

Ортодонтия

UDC 616.314.26-007.26-76-089

**INFLUENCE OF THE SUS APPLIANCE ON THE MAXILLO-FACIAL SYSTEM
AND TMJ IN ADULT PATIENTS WITH SKELETAL CLASS II MALOCCLUSION
DETERMINED BY THE RETROPOSITION OF LOWER JAW**

**I. Tokarevich,
E. Kolomiets**

Belorussian State Medical University, Minsk

**ВЛИЯНИЕ АППАРАТА SUS НА ЗУБОЧЕЛЮСТНО-ЛИЦЕВУЮ СИСТЕМУ И ВНЧС
У ВЗРОСЛЫХ ПАЦИЕНТОВ С ДИСТАЛЬНЫМ СКЕЛЕТНЫМ ПРИКУСОМ,
ОБУСЛОВЛЕННЫМ РЕТРОПОЛОЖЕНИЕМ НИЖНЕЙ ЧЕЛЮСТИ**

**И. В. Токаревич,
Е. Г. Коломиец**

Белорусский государственный медицинский университет,
г. Минск

Class II malocclusion is a consequence of deflection of anatomic-topographic correlations on various morphological levels [2]. Besides negative influence on psycho-emotional status of a patient and significant changes in maxillo-facial area, this pathology effects negatively the function of TMJ and face esthetics of a patient as well.

Today there is a large group of intermaxillary a fixed functional appliances, providing correction of skeletal Class II due to extension of mandible, which afford us to reach full interocclusal correlations of jaws and harmonization of face profile without extracting teeth or orthognatic surgery on jaws [1, 6, 7, 8]. From our point of view, one of most successful representatives of this group is Sabbagh's universal spring (SUS).

The aim of the present study was to analyze of influence of SUS on maxillo-facial system and TMJ in adults with skeletal Class II malocclusion, determined by retroposition of lower jaw.

Materials and methods: investigation passed on the chair of orthodontics of BSMU, in Republic clinical dental polyclinic. In aim to achieve the goal of query, there were studied side lateral cephalograms, 3D-computer tomograms of TMJ, MRI of TMJ of 38 patients, who finish orthodontic treatment of Class II malocclusion by extension of lower jaw with the help of SUS.

Middle value of saggital slot of the patients with distal bite before treatment made 7.73 ± 0.4 mm.

Middle duration of treatment by muldibonding system combined with SUS made in average 24.2 ± 0.94 months. Average age of patients after orthodontic treatment made 20.0 (17.0 – 24.0) years old.

For analysis of changing parameters of facial skelet before and after the treatment in cured patients we use methods, suggested by I. Tokarevich [5], F. Horoshilkina [2], R. J. Paolo [2], A. M. Schwarz [4], A. Bjork [3], G. Steiner [3], profile of lips was examined relatively to esthetic line of Ricketts [3].

X-ray study of TMJ was held on a cone-beam tomograph CB500 (Gendex powered by iCat). Examination of TMJ of 38 patients was made with closed mouth and open mouth till 4 cm.

Magnetic Resonance Imaging of TMJ, as an additional method of research, was made on high field MRI scanner Intera 1.5 T (Philips). All in all 22 MR examinations of TMJ with closed and open mouth were made. The obtained data were processed statistically.

Results and discussion. On the base of analysis of lateral cephalograms results of 38 patients with skeletal Class II, after the orthodontic treatment, it was claimed that a statistically reliable

Linear and angular parameters of analysis of lateral cephalograms before and after the treatment of patients with skeletal Class II

Table 1.

Linear and angular parameters	Index value before treatment		Index value after treatment		Reliability of differences
	M	SD	M	SD	
SNA, °	82,12	3,91	82,76	3,51	p > 0,05
SNB, °	75,64	3,84	77,63	3,59	p < 0,001
SNPg, °	77,96	3,99	79,63	3,91	p > 0,001
ANB, °	6,47	1,55	5,13	1,61	p < 0,001
Wits (mm)	4,53	1,06	2,16	0,82	p < 0,001
A'-PNS (mm)	53,50	2,58	53,88	2,45	p > 0,05
B'-J' (mm)	52,20	3,27	54,04	3,13	p < 0,001
A'-B' (mm)	61,46	6,26	63,24	4,73	p < 0,01
PNS-J' (mm)	42,96	4,78	45,13	4,74	p < 0,001
NSMP, °	27,47	6,16	27,33	5,63	p > 0,05
SpPMP, °	20,33	5,83	20,11	5,13	p > 0,05
OcpMP, °	14,66	4,35	11,95	4,27	p < 0,001
NSAr, °	123,22	6,00	122,89	4,68	p > 0,05
SArGo, °	143,37	7,38	143,87	6,28	p > 0,05
ArGoMe, °	122,17	6,21	120,68	5,99	p < 0,05
S-Go (mm)	80,01	6,35	82,28	6,57	p < 0,001
N-Gn (mm)	115,22	7,84	115,78	6,92	p > 0,05
I-SpP, °	113,14	12,00	108,24	7,72	p < 0,05
I-NA, °	23,39	9,84	18,23	7,03	p < 0,01
-MP, °	98,55	5,44	101,47	4,64	p < 0,05
-NB, °	26,13	6,16	31,34	3,71	p < 0,001
PnH, °	83,50	2,90	85,03	3,11	p < 0,05
PnOcP, °	77,66	5,38	74,95	4,05	p < 0,001
NAB, °	161,50	5,25	164,53	4,06	p < 0,001
n-sn-pg, °	157,29	8,79	160,32	7,56	p < 0,05
n-ns-pg, °	123,21	5,83	124,55	6,44	p > 0,05
UL-E line (mm)	-3,09	3,44	-5,09	3,26	p < 0,001
LL-E line (mm)	-1,63	3,76	-2,41	3,57	p > 0,05

increase of angular parameter SNB, SNPg, NAB and linear parameter B'-J', as well as decrease of angular parameter ANB and linear - Wits-number took place. Whereas changes of angular parameter SNA and linear A'-PNS were not identified.

Treatment results of distal bite allow to claim, that in vertical plane in examined patients, general back height of face increase due to increasing size of down back height of facial skeleton. Also during the treatment angular parameters OcpMP, PnOcP decreased, which proves changing of inclination angle of occlusal plane, which happens during the use of SUS. Besides, in examined group of patients a significant increase of angular parameter PnH and decrease of ArGoMe angle, during extrusion of mandible, were established.

Results of studying of side TRG on dentoalveolar level evidence that, during the treatment process, under the influence of Sabbagh universal spring, upper incisors incline palatally and appear close to normal position, meanwhile down incisors protrude.

Flattening of profile among these patients during the treatment occurs due to the change of upper lip position relatively to esthetic line (E-line). Upper lip became reliably flatter, at the same time down lip remain without significant changes. In the treatment process face convexity of the patients decrease, due to growth of angular parameter of soft-tissue profile (considering nose) and skeletal profile (table 1).

According to the collected data, it was identified that after the treatment, among the patients who had complaints about TMJ, a 'clicking' symptom remain in 4 cases, 1 patient marked contravention of excursion of the head of lower jaw, in 1 case remained difficult mouth opening. There were no complaints noted, connected with painful feelings or discomfort in the joint projection after the treatment.

Table 2

Change of width of articular spaces of right and left TMJ in patients with distal bite after the treatment

TMJ	Articular space (part)	Size of articular space before treatment		Size of articular space after treatment		Reliability of differences
		M	SD	M	SD	
Left	Front	2.55	0.60	2.06	0.39	p < 0.001
	Upper	2.93	0.61	3.73	0.73	p < 0.001
	Distal	3.23	0.74	3.71	0.53	p < 0.01
Right	Front	2.59	0.61	2.03	0.38	p < 0.001
	Upper	2.91	0.68	3.78	0.70	p < 0.001
	Distal	3.06	0.84	3.74	0.53	p < 0.001

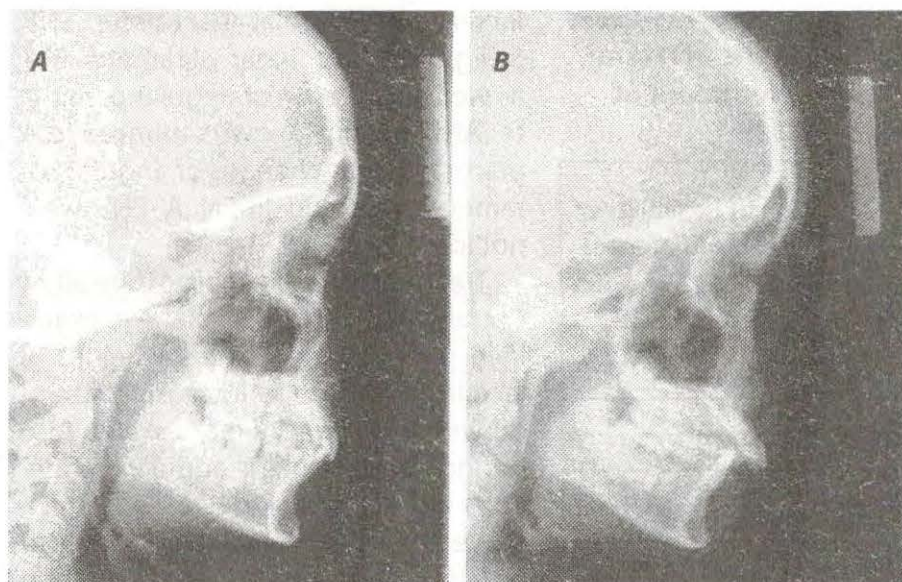


Figure 1. Lateral cephalometric radiographs. (A) Pretreatment (16 years 7 months). (B) Posttreatment (18 years)

The absence of complaints about pain in TMJ is explained by complex anti-inflammatory therapy, including medicamental and physiotherapeutic combined treatment, which was presented among all patients with identified inflammatory process in TMJ before starting the orthodontic treatment.

Results of study of TMJ on the base of analysis of cone-beam tomograms, show that in the patients who finish orthodontic treatment of distal bite by extension of lower jaw, articular head of both TMJ in the treatment process move down and forward, which is proved by growth of upper and back parts of articular cavity sizes, and reduce

of front part of articular cavity. The data obtained are presented in **table 2**.

Analysis of right and left TMJ articular heads position relatively to articular tubercle during the maximum allowable mouth opening let us claim that after the treatment in the examined group of the patients, the frequency of occurring location of right and left articular heads at the top of articular tubercle statistically reliably increased ($p < 0.001$).

Also no data about possible changing or structure damages of TMJ bone elements were detected.

Confirming the presented results of cone-beam tomography and analysis of MRI of TMJ, received after the treatment of patients with distal bite, we claim that in the treatment process articular head move forward and down relatively to bottom of the articular fossa.

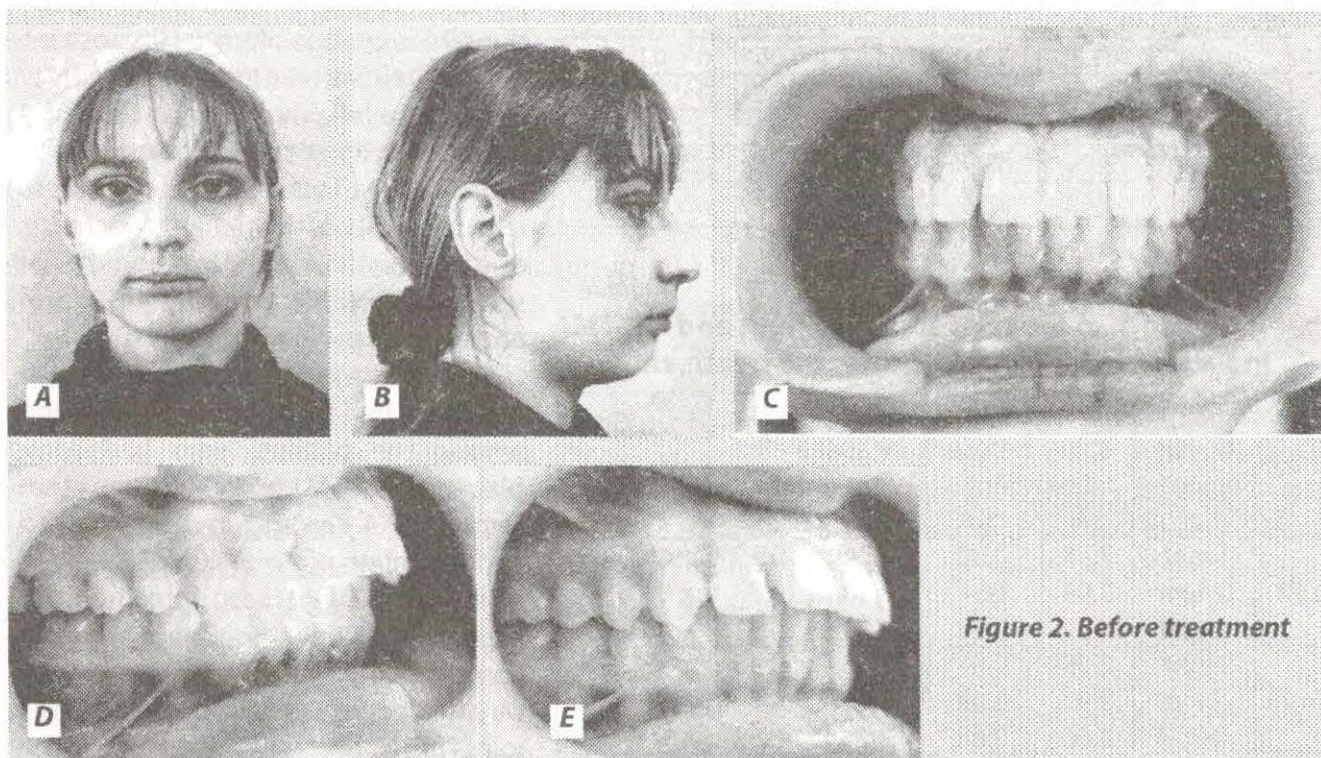


Figure 2. Before treatment

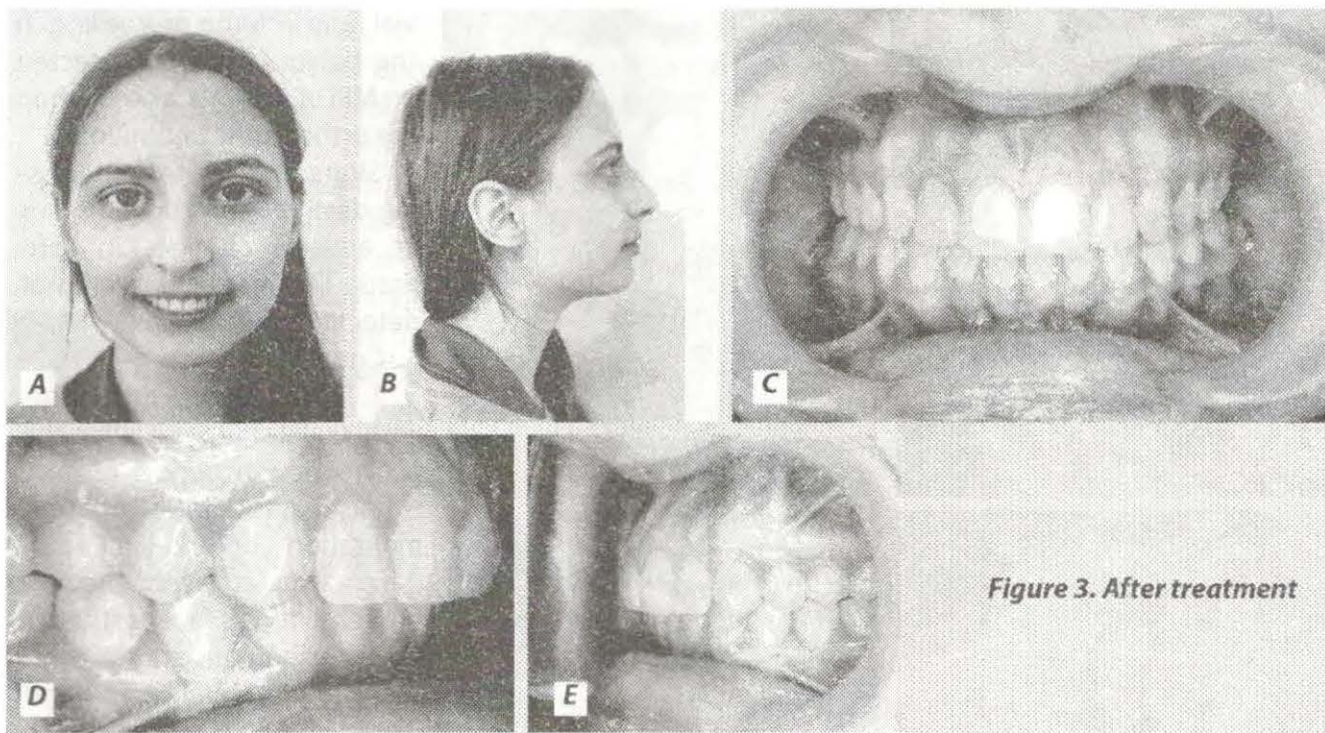


Figure 3. After treatment

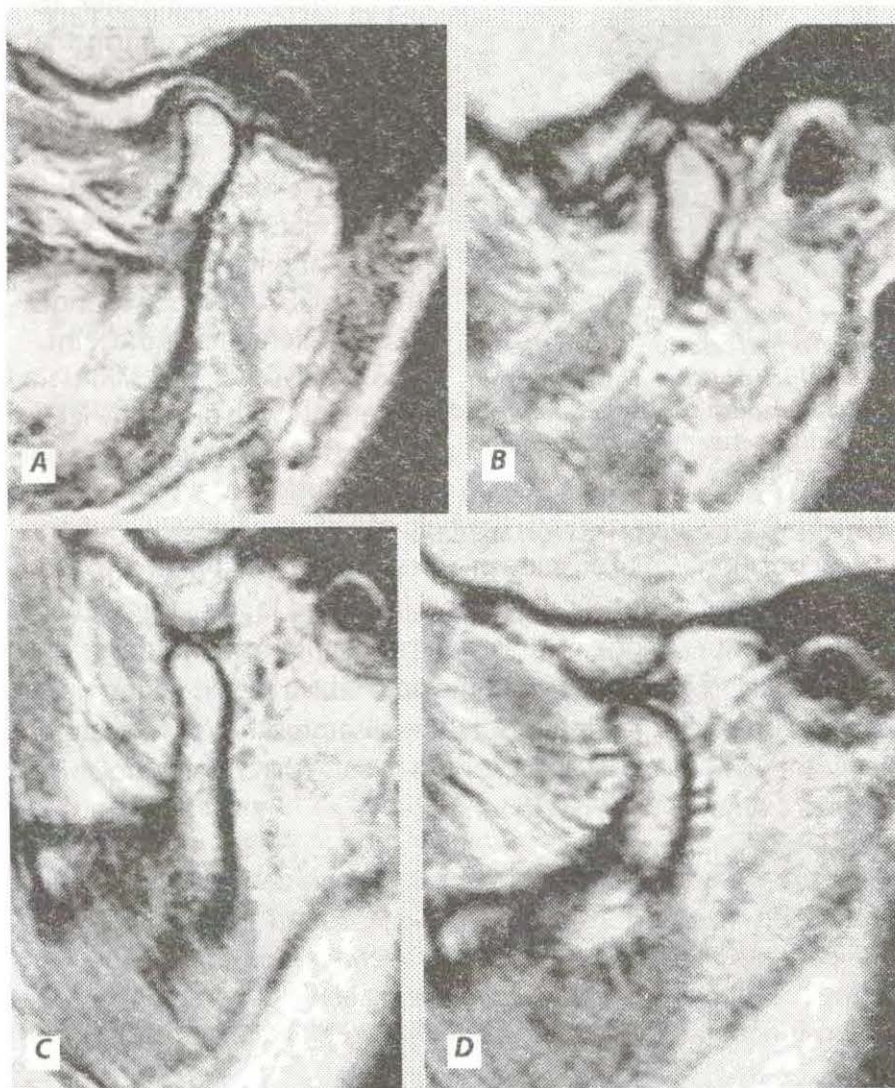


Figure 4. MR imaging of the TMJ before treatment: (A) A closed-mouth sagittal T1-weighted image shows a normal relationship of the mandibular condyle, the disk at the 11 o'clock position, the temporal fossa and the articular eminence; (B) Closed-mouth sagittal T1-weighted image shows the anteriorly displaced disk; (C, D) Open-mouth sagittal T1-weighted images shows the normal position of the disk between the mandibular condyle and articular eminence

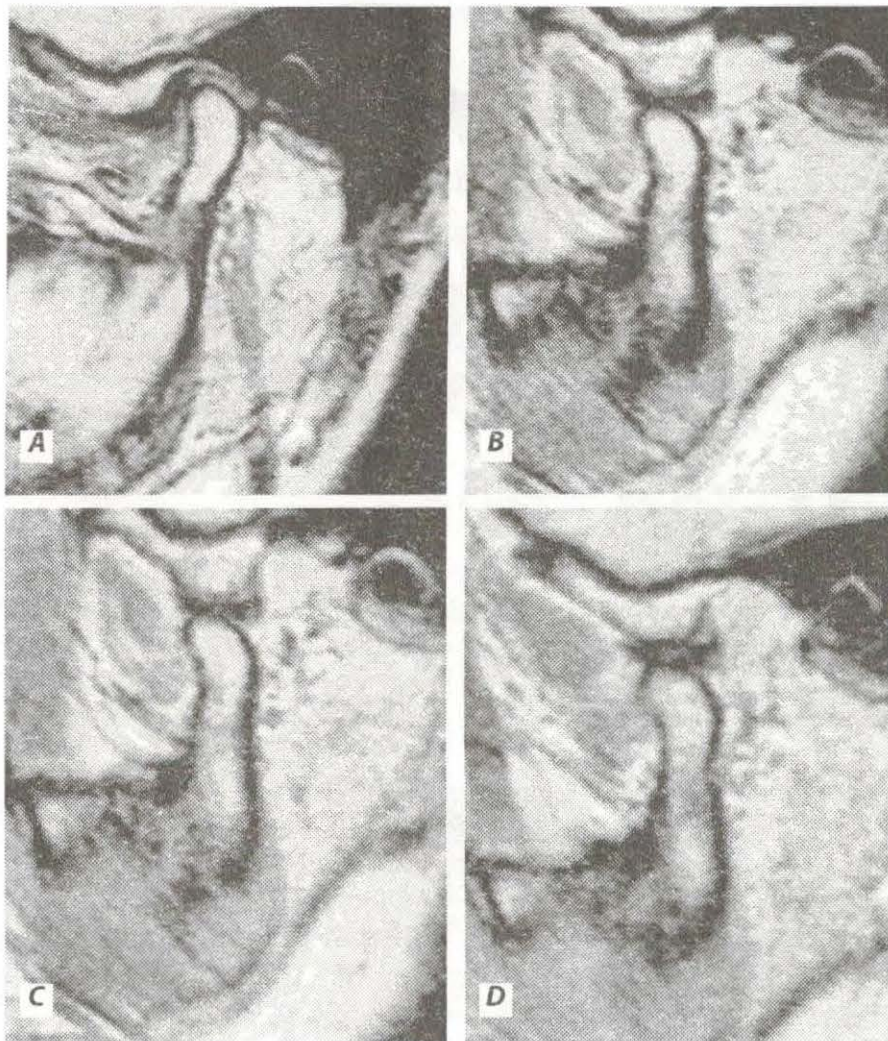


Figure 5. MR Imaging of the TMJ after treatment: (A, B) A closed-mouth sagittal T1-weighted images shows a normal relationship of the mandibular condyle, the disk at the 11 o'clock position, the temporal fossa and the articular eminence; (C, D) Open-mouth sagittal T1-weighted images shows the normal position of the disk between the mandibular condyle and articular eminence

Study of TMJ soft-tissue structures show, that after the treatment frequency of normal position of articular discs in habitual occlusion increase reliably ($p < 0.01$), specially in the cases without signs of their deformation marked earlier.

Frequency of inflammatory processes in the TMJ cavity after the treatment significantly decrease ($p < 0.001$). There was no increase of syn-

vial fluid volume or swelling in the behind-disc area detected on MRI of patients who finished the orthodontic treatment.

Signs, indicating progressing destruction in bone tissues or adverse changes in soft-tissue TMJ elements, were not detected as well.

Conclusions.

1. The use of SUS in patients with skeletal Class II after the active growth period of jaws is finished, facilitates bite normalization on skeletal and dento-alveolar levels and improvement of face esthetics by reducing convexity of soft-tissue and skeletal profile, and flattening of upper lip as well.

2. Study of computer tomograms of TMJ confirm that after extension of lower jaw by SUS articular head in habitual occlusion took a front-down position relating to the bottom of articular fossa, at the same time patients with osteoarthritis didn't produce changes in bone elements of the joint.

3. Analysis of TMJ MRI data of patients with distal bite let us claim, that after treating Class II malocclusion by extension low-

er jaw with the help of SUS, the frequency of normal position of articular discs in habitual occlusion statistically reliably increased in the cases without signs of their deformation before the treatment. At the same time data which would confirm progressing destructive disorders in bone structures, or adverse changes in soft-tissue elements of TMJ were not identified.

REFERENCES:

1. Alvetro, L. (2009), «Correction of the distal occlusion of class II using Forsus: the predictability of results and independence of patients. Practical overview», *Ortodontiya*, no. 2, pp. 56–58.
2. Khoroshilkina, F. Ya. et al. (1987), *Diagnostika i funktsionalnoe lechenie zubocheiliustnolitseyvykh anomalij* [Diagnosis and functional treatment of maxillofacial anomalies], Meditsina, Moscow, USSR.

3. Netsei, F. and Shults, K. (2006), *Prakticheskoe rukovodstvo po ortodonticheskoi diagnostike. Analiz i tablitsy dlya ispolzovaniya v praktike* [A Practical Guide to orthodontic diagnosis. Analysis and tables for use in the practice], Lviv, Ukraine.
4. Persin, L. (2007), *Ortodontiya. Sovremennyye metody diagnostiki zubocheiliustno-litsevykh anonalij* [Orthodontics. Modern methods of diagnosis of maxillofacial anomalies], Moscow, Russian Federation.
5. Tokarevich, I. (1986), «Planning and forecasting of treatment of distal occlusion with a protrusion of the maxillary incisors», Abstract of Cand. Sci. (Med.) dissertation, 14.00.21, Belorussian State Institute of Advanced Training of Physicians, Minsk, Belorussia.
6. Jasper, J. J. and McNamara, J. A. (1995), «The correction of interarch malocclusions using a fixed force module», *Am. J. Orthod*, Vol. 108, no. 6, pp. 641–650.
7. Pancherz, H. (1985), «The Herbst appliance: Its biologic effects and clinical use», *Am. J. Orthod*, Vol. 87, no. 1, pp. 1–20.
8. Sabbagh, A. (2007), «Front extension of the mandible is a progressive «jump» of occlusion using SUS», *Suchasna ortodontiya*, no. 1, pp. 8–15.

Abstract

INFLUENCE OF THE SUS APPLIANCE ON THE MAXILLO-FACIAL SYSTEM AND TMJ IN ADULT PATIENTS WITH SKELETAL CLASS II MALOCCLUSION DETERMINED BY THE RETROPOSITION OF LOWER JAW

I. Tokarevich, E. Kolomiets

Class II malocclusion in adults is the most frequent problem in the orthodontic. The aim of the present study was to analyze the skeletal and dentoalveolar changes and to evaluate the condition of TMJ in Class II malocclusion cases treated with the Sabbagh universal spring. TMJ and cephalometric analysis of skeletal and dentoalveolar facial structures of 38 patients with Class II malocclusion treated with SUS was performed using the same reference system before and after the treatment. TMJ remodeling was analyzed by magnetic resonance imaging and 3D-computer tomography.

Keywords: Class II malocclusion, Sabbagh universal spring, TMJ, lateral cephalograms.

Резюме

ВЛИЯНИЕ АППАРАТА SUS НА ЗУБОЧЕЛЮСТНО-ЛИЦЕВУЮ СИСТЕМУ И ВНЧС У ВЗРОСЛЫХ ПАЦИЕНТОВ С ДИСТАЛЬНЫМ СКЕЛЕТНЫМ ПРИКУСОМ, ОБУСЛОВЛЕННЫМ РЕТРОПОЛОЖЕНИЕМ НИЖНЕЙ ЧЕЛЮСТИ

И. В. Токаревич, Е. Г. Коломиец

Лечение дистального прикуса у взрослых пациентов является наиболее часто встречаемой проблемой в ортодонтии. Целью настоящего исследования явилось изучение скелетных и зубоальвеолярных изменений, а также оценка состояния височно-нижнечелюстного сустава после проведенного лечения дистального скелетного прикуса посредством выдвигания нижней челюсти при помощи универсальной пружины Саббаха.

Для достижения поставленной цели были изучены боковые телерентгенограммы головы, 3D – компьютерные томограммы ВНЧС, магнитно-резонансные томограммы ВНЧС пациентов, закончивших ортодонтическое лечение дистального прикуса посредством выдвигания нижней челюсти при помощи SUS. Полученные результаты позволили установить, что аппарат SUS является эффективным инструментом в коррекции дистального прикуса у взрослых пациентов.

Ключевые слова: II класс по Энгля, универсальная пружина Саббаха, височно-нижнечелюстной сустав, боковая телерентгенограмма головы.